

UNIT 1

SYSTEM APPROACH TO THE HUMAN BODY

ANATOMY

Human anatomy is the branch of science which deals with the structure of the human body. The term 'anatomy' is derived from a Greek word "anatome" which means cutting up (dissection).

Herophilus of Chalcedon (circa 300 BC) is called the 'father of anatomy'. He was a Greek physician, and was one of the first to dissect the human body.

PHYSIOLOGY

Human physiology is the branch of science, which deals with the functions of various parts of normal body. It also includes the study of physical and chemical changes which take place in the body.

REGIONS OF THE BODY

Human body is divided into five major regions that can be identified externally.

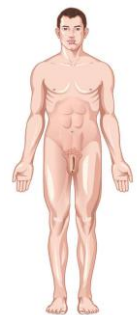1. **Head:** Head consists of the skull and face.
2. **Neck:** Neck supports the head and attaches it to the trunk.
3. **Trunk:** Trunk consists of the chest, abdomen and pelvis.
4. **Upper limbs:** Each upper limb consists of the arm, forearm and hand.
5. **Lower limbs:** Each lower limb consists of the buttock, thigh, leg, ankle, and foot.

POSITIONS OF THE BODY

The attitude or posture of the body is known as body position. The body position is:

a. **Anatomical position**

- The body is erect (straight) in standing position with eyes looking forwards.
- The both arms hang on either side of the body and the palms facing forwards.
- The legs are parallel, with feet flat on the floor and facing forward.



b. **Supine position:** A person is lying on her/his back, arms by the side, palms facing upwards and feet put together is known as supine position.

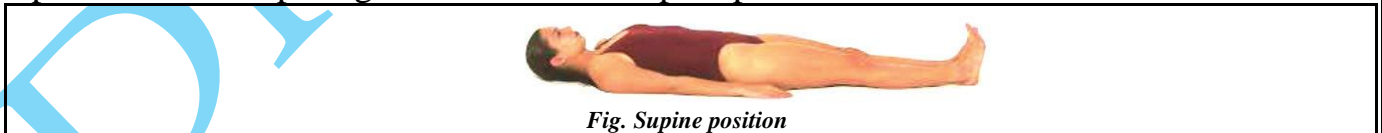

Fig. Supine position

c. **Prone position:** In this position, a person lying on his/her face, chest and abdomen is said to be in downward.

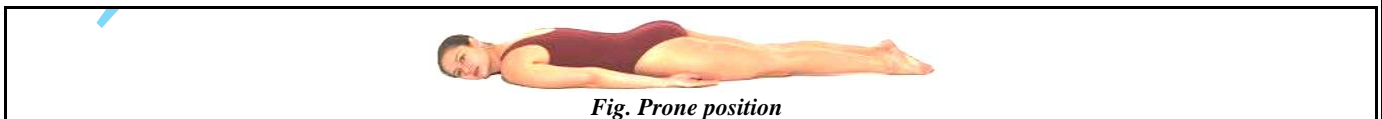

Fig. Prone position

d. **Lithotomy position:** A supine position of the body with the legs separated, flexed, and supported in raised stirrups. This position is mostly used during delivery.

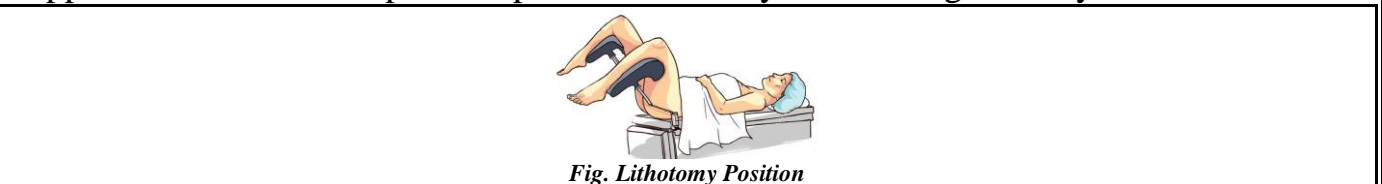


Fig. Lithotomy Position

ANATOMICAL PLANES/BODY PLANES

The anatomical planes are imaginary lines used to divide the body into sections. They are used to describe the location of structures in human anatomy. The anatomical planes are:

- a. Median or midsagittal plane:** A plane passing through the centre of the body dividing into two equal right and left halves is known as median plane or midsagittal plane.
- b. Coronal or frontal plane:** A plane which divides the body vertically into anterior (front) and posterior (back) parts or section is known as coronal or frontal plane.
- c. Transverse or horizontal plane:** A plane which divides the body horizontally into superior (upper) and inferior (lower) part or section is known as transverse or frontal plane. It is also known as cross-section.
- d. Oblique plane:** Any plane other than coronal, transverse and midsagittal is known as oblique plane.

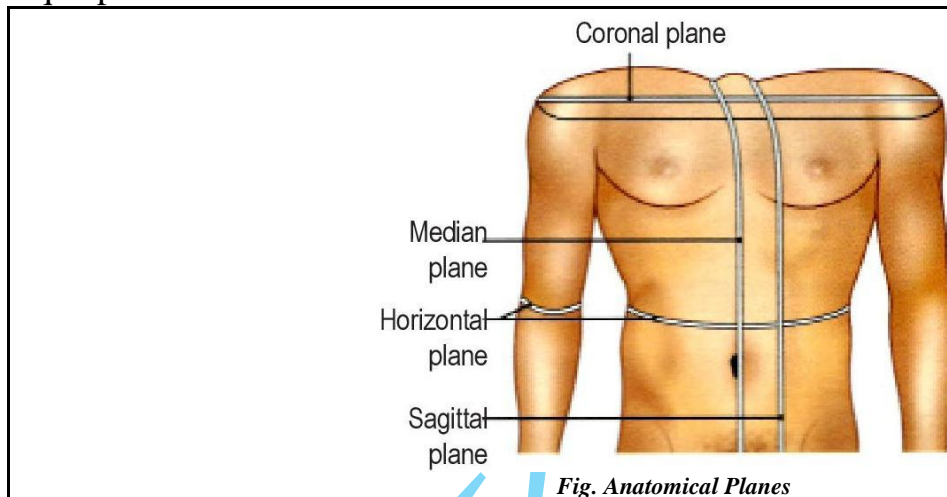


Fig. Anatomical Planes

ANATOMICAL TERMS

1. Anterior /Ventral : Towards the front
2. Posterior/Dorsal : Towards the back
3. Superior : Towards the head (up)
4. Inferior : Towards the feet(down)
5. Medial : Towards the median plane
6. Lateral : Away from the mid line
7. Proximal : Nearer to the trunk
8. Distal : Away from the trunk
9. Palmar or volar : Palm of the hand
10. Plantar : Sole of the foot

TERMS USED IN BODY MOVEMENTS

The motion of all or part of the body, especially at a joint or joints is known as body movements. The body movements are:

No	Movements name	Definition
1.	Flexion	The movement by which the angle of a joint is decreased is known as flexion. Examples: Bending the elbow joint, bending the knee joint, bending forward at the waist.
2.	Extension	The movement by which the angle of a joint is increased is known as extension. Examples: Straighten the forearm at the elbow joint, knee joint in standing position.

3.	Adduction	The movement towards the central axis (mid line) is known as adduction. Example: Limb is brought close to the body.
4.	Abduction	The movement away from the central axis (mid line) is known as abduction. Example: Limb is taken away from the body.
5.	Medial rotation	The rotation toward the medial side of the body is known as medial rotation. Example: At the hip joint can be brought about by internally rotating a fully extended lower limb, such that the big toe points inwards.
6.	Lateral rotation	The rotation towards the lateral side of the body is known as lateral rotation. Example: The lateral rotation at the hip joint can be brought about by externally rotating a fully extended lower limb, such that the big toe points outwards.
7.	Circumduction	The circular movement of a body part such as a ball and socket joints is known as circumduction. It consists of combination of flexion, extension, adduction and abduction. Example: When the arm is performing in circular direction.
8.	Rotation	The movement around a central axis involves 360° is known as rotation.
9.	Supination	The movement occurs in the forearm where by the palm is turned forwards is known as supination.
10.	Pronation	The movement occurs in the forearm where by the palm is turned backwards is known as pronation.
11.	Opposition	The tip of thumb touches the tips of any of the fingers are known as opposition.

BODY CAVITIES

The hollow space or potential space surrounded by bones and muscles in which vital and delicate organs are contained within the body is known as body cavities. The body organs are contained and protected within four cavities.

- Cranial cavity
- Thoracic cavity
- Abdominal cavity
- Pelvic cavity

1. **Cranial cavity:** The cranial cavity contains the brain and its boundaries are formed by the bones of the skull.

2. **Thoracic cavity:** Thoracic cavity is situated in the upper part of the trunk. Its boundaries are formed by a bony frame work and supporting muscles. It contains:

- Trachea
- Bronchi
- Lungs
- Heart
- Aorta
- Superior Venacava
- Inferior venacava
- Oesophagus
- Blood vessels
- Lymph vessels
- Nerves

3. **Abdominal cavity:** Abdominal cavity is the largest cavity in the body. It is situated in the main part of the trunk. The abdominal cavity is divided into nine regions. It facilitates the description of the positions of the organs and structures.

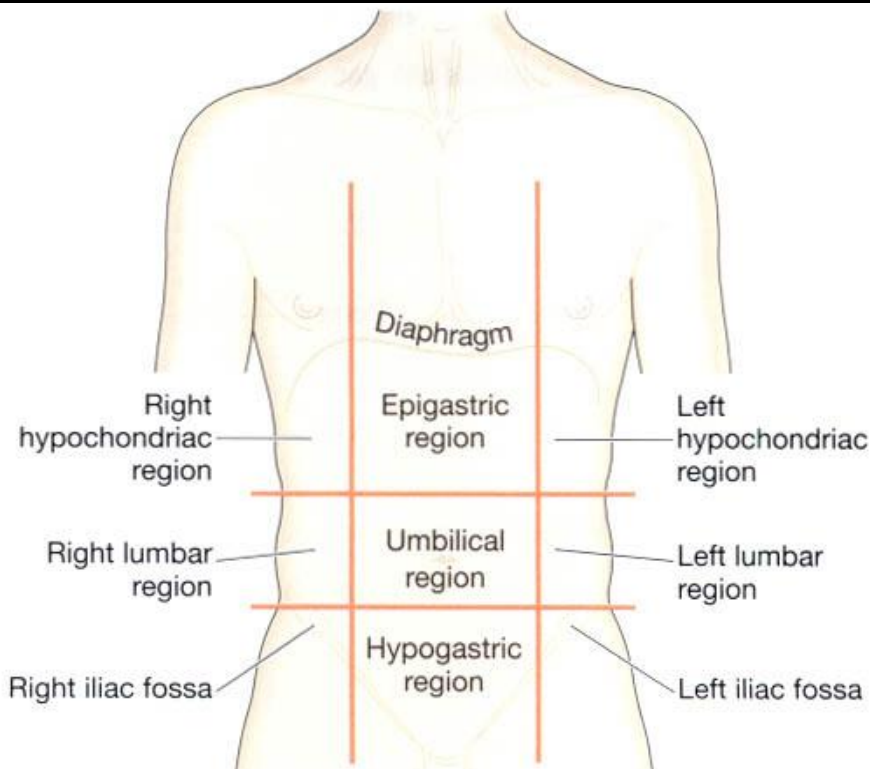


Fig: Nine regions of the abdominal cavity

Contains:

The abdominal cavity contains liver, stomach, gall bladder, small intestine, kidneys, oesophagus, pancreas, spleen, adrenal glands, ureters etc.

4. **Pelvic cavity:** Pelvic cavity extends from the lower end of the abdominal cavity.

Contains:

Pelvic cavity contains sigmoid colon, rectum, anus, urinary bladder, lower part of ureters and urethra.

- **In female:** The organs of the reproductive system are vagina, uterus, uterine tube, and ovaries.
- **In male:** The organs of the male reproductive system are prostate gland, seminal vesicles, spermatic cords, vas deferens, ejaculatory ducts and urethra.

System Approach to the Human Body
Prepared By: Dr.C K Singh